

# PHYSICIAN REPORT

SPECIAL 2020 EDITION



> REGINALD WASHINGTON, MD, FAAP, FACC, FAHA  
Chief Medical Officer

Rocky Mountain  
Hospital for  
Children and  
Presbyterian/  
St. Luke's Medical  
Center

720-754-6000

## INSIDE

Adult and Pediatric  
Teams Collaborate  
to Support High-  
Risk Mom and Baby  
> page 2

Highlighted  
Publications by  
Our Physicians  
> page 5

Expanding  
Liver Transplant  
Options for Adults  
and Children  
> page 7

Be Proactive: It's  
Like Hand Hygiene  
for Cybersecurity  
> page 8

## A Note from Dr. Washington

**W**elcome to a special joint issue of the Rocky Mountain Hospital for Children (RMHC) and Presbyterian/St. Luke's Medical Center's (P/SL) *Physician Report*. In this report, we highlight the personal approach taken by our anesthesia teams, the benefits of having access to multidisciplinary care for high-risk moms and babies, unique qualities of our liver transplant program and publications by our own P/SL and RMHC physicians. Finally, as we kick off 2020, we'll help you stay more cyber secure.

Sincerely,

Reginald Washington, MD,  
FAAP, FACC, FAHA  
Chief Medical Officer

## BEYOND THE SURGICAL CURTAIN: Anesthesiology at P/SL and RMHC

**O**n the day of surgery, the anesthesia team at Presbyterian/St. Luke's Medical Center (P/SL) and Rocky Mountain Hospital for Children (RMHC) has to confirm a patient's medical history and establish rapport with the patient. Some may think that they spend relatively little time with patients, but their connection with the patient can start before the day of surgery. They believe in the value of connecting with and understanding the unique needs, wants and fears of each patient.

Whether the procedure requires sedation, general, local, or regional anesthesia, the anesthesiologists take time before and after each procedure to design an appropriate anesthesia plan while building rapport and trust.

"The beauty of the medicine we provide is the personal aspect of delivering anesthesia to that particular patient with that unique medical history," says Bridget Bailey, DO, USAP anesthesiologist and anesthesia chair at P/SL.

Even when the anesthesia plan seems straightforward, unforeseen complications can arise, so anesthesiologists are required to quickly adapt and care for patients with plan A, B and C in mind.

(continued on page 4)



> Bridget Bailey, DO,  
Anesthesia  
Chair, P/SL



> Annette  
Michael, MD,  
Anesthesia Site  
Chief, RMHC



Like and  
Follow Us!



1719 East 19<sup>th</sup> Avenue, Denver, CO 80218 | 720.754.6000  
www.PSLMC.com | www.RockyMountainHospitalForChildren.com  
Mari.Abrams@HealthONEcares.com

# ADULT AND PEDIATRIC TEAMS COLLABORATE to Support High-Risk Mom and Baby

A baby boy born nearly 10 weeks prematurely and with a life-threatening congenital heart defect recently celebrated his first birthday following diligent care he and his mother received from the medical teams at Presbyterian/St. Luke's Medical Center (P/SL) and Rocky Mountain Hospital for Children (RMHC). The adult and pediatric physicians worked together to care for mom and baby, something made possible because of the unique campus that combines both a Level IV Maternal Program and Level IV NICU.

The mother was admitted to P/SL at 24 weeks, five days gestation with leaking membranes. Maternal-fetal medicine specialist Oliver Jones, MD, saw her initially and helped manage her care. The doctors performed an amniocentesis and checked for infection, which was negative. A fetal ultrasound confirmed severe heart abnormalities.

After staying in the hospital for a week, the patient requested to go home to help

care for her other children. After talking with the patient, who trained as a doctor in her native country, Dr. Jones and his colleagues allowed her to return home as long as she visited the practice regularly to monitor her amniotic fluid.

"There are some data that shows with certain criteria, managing ruptured membranes on an outpatient basis isn't unreasonable," says Dr. Jones, who says the mother's medical knowledge and understanding of the risks made the agreement possible.

## STAYING PERSISTENT

Dr. Jones continued regular evaluation of the mother. Five weeks later, she returned to the hospital reporting decreased fetal movement. Tara Becker, MD, delivered the patient's son days later, at 31 weeks and one day gestational age via cesarean section. The newborn weighed 1.6 kg at birth and was born with pulmonary atresia and a ventricular septal defect.

"There was a ventricular septal defect or VSD and no connection between the heart



This is the 3D model of the patient's heart used to help confirm surgical approach.



> Tara Becker, MD, Adult & Pediatric Congenital Heart Cardiologist



> Abhay Divekar, MD, Adult Congenital Heart Cardiologist



> Oliver Jones, MD, Maternal Fetal Medicine Specialist



> Steven Leonard, MD, Pediatric Cardiac Surgeon



> Michael Petterson, MD, Pediatric Cardiologist



## “The whole system has to work and it did.”

-Abhay Divekar, MD

and lungs,” says Steven Leonard, MD, a pediatric cardiac surgeon at RMHC who performed the newborn’s two heart operations. “Blood was supplied to his lungs through the patent ductus arteriosus — a blood vessel that is present in all babies before birth, but closes in the first several days of life.”

As such, the newborn required constant infusion of prostaglandin via a central venous catheter. Because he was premature, the newborn spent almost two months in the NICU receiving intravenous nutrition so that he could grow enough to undergo surgery. In the NICU, he battled chronic lung disease, temperature instability and a severe infection.

### A SURGICAL PATH

About two months after birth, Dr. Leonard performed the newborn’s first operation, a palliative operation to provide blood flow to the lungs. This would allow him to leave the hospital since he would no longer be dependent upon the PDA to survive.

Dr. Leonard placed a shunt between the right ventricle and pulmonary artery to provide blood flow to the lungs. In addition, narrowing in the left pulmonary was enlarged with a small patch and the PDA was closed.

After more than two months of complicated recovery, which included placement of a feeding tube and the clearing of blood clots

in one of his blood vessels, the newborn went home.

He returned to the hospital when a routine childhood virus landed him in the PICU for more than a month. Once he recovered, the infant underwent a “marathon day” of testing under anesthesia, including a hearing test, an MRI of the heart, heart catheterization and a comprehensive echocardiogram, according to RMHC adult and pediatric congenital heart specialist Abhay Divekar, MD.

Dr. Divekar and his colleague Michael Pettersen, MD, used the information to have a hollow 3D diagram of the newborn’s complex heart printed to confirm the surgical approach.

“The main question was when Dr. Leonard closed the hole, would there be enough space in the right lower chamber for it to have an effective pump,” Dr. Divekar says.

The model lent additional

confidence to the approach, and Dr. Leonard performed surgery on the baby in late July 2019. “This was an open-heart operation in which the ventricular septal defect was closed to direct blood from the left ventricle to the aorta, the shunt was removed, and a connection was made between the right ventricle and pulmonary artery using a tube graft containing a valve.”

The surgery was a success, and after a three-week recovery in the PICU, the baby returned home. His outlook is positive. He will eventually require another operation to replace the graft between the right ventricle and pulmonary artery, but hopefully not for several years, Dr. Leonard said.

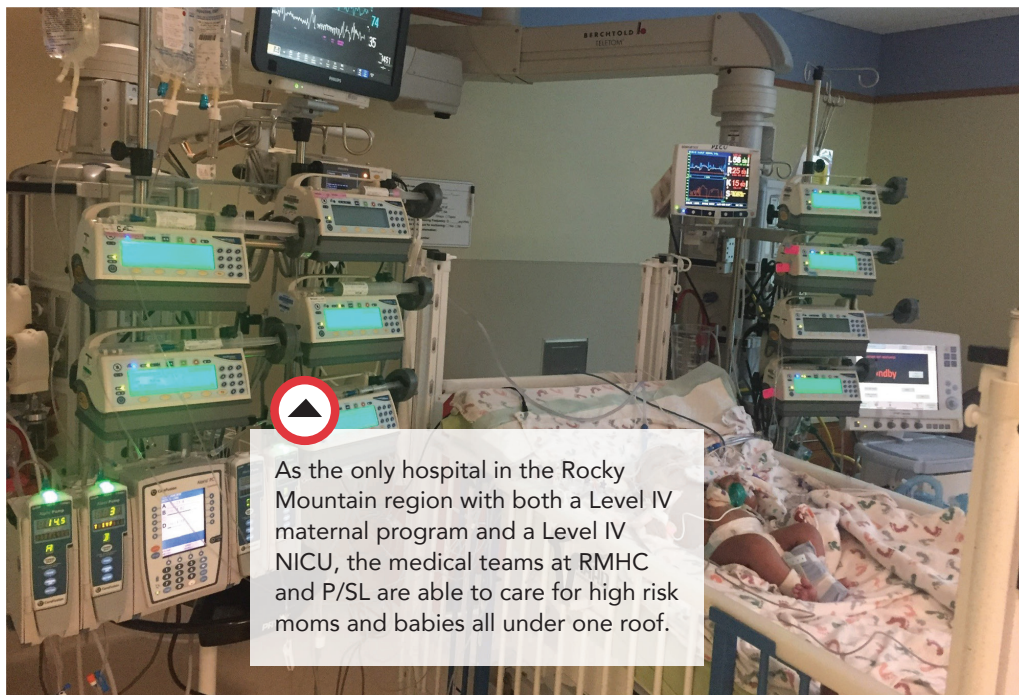
Caring for this high-risk mom and baby was no easy task.

“Mom received expert care from the maternal-fetal medicine team. Cardiac care

began in the prenatal period and continues to this day. After delivery, the newborn received incredible care in the neonatal intensive care unit and the pediatric intensive care unit. He has had innumerable physicians involved in his care, including neonatologists, pediatric intensivists, cardiologists, cardiac surgeons, anesthesiologists, pediatric surgeons, pediatric gastroenterologists, pediatric hematologists and pediatric pulmonologists,” says Dr. Leonard.

“All along, the newborn and his mother have been helped by maternal-fetal, neonatal and pediatric navigators. It is impossible to completely describe and thank the multitude of caregivers that have been involved,” says Dr. Leonard.

“It’s hard to name everyone involved,” Dr. Divekar agrees. “The whole system has to work and it did.”



As the only hospital in the Rocky Mountain region with both a Level IV maternal program and a Level IV NICU, the medical teams at RMHC and P/SL are able to care for high risk moms and babies all under one roof.

*Beyond the Surgical Curtain (continued from page 1)*

A few examples of unforeseen complications are: airway issues, blood transfusions, changing from sedation to a general anesthetic, bronchospasm and adapting to unanticipated blood loss.

“Ninety percent of the time, the expected is what happens. It’s the other 10 percent where we have to think on our feet. We often have to act like the ICU physicians of the operating room or the ICU nurse anesthetists,” Dr. Bailey says. “We try to handle complications with ease and make sure that the surgeon can finish the case. It’s a very beautiful relationship we have with every member of the team; surgeons, PAs, OR circulating room nurses, surgical assists, preop and PACU, and many others as part of the patient’s surgical experience at P/SL and RMHC.”

Dr. Bailey adds that because of the unique pharmacology for anesthesia medication used, such as paralytics and narcotics, there is a unique subset of complications that can occur in recovery. Thus for all of our patients at P/SL and RMHC, the preop and intraoperation are important, but the post-operation is equally critical. The anesthesia team works closely with PACU nurses who are well prepared for unlikely but possible complications ranging from lung complications to cardiac arrest.

Annette Michael, MD, is anesthesia site chief for RMHC, working with the smallest patients. The team provides services for pediatric general surgery, urology, ENT, neurosurgery, orthopedics, spine surgery and much more. Additionally, they administer anesthesia for several radiology procedures including MRI and CT.

#### HELPING THE TINIEST OF PATIENTS

At RMHC, there are subspecialties within pediatric anesthesia. A very specialized group of three anesthesiologists specializes in cardiac anesthesia, which includes open-heart surgery cases as well as cardiac catheterization cases in children; another team specializes in spine surgery; another team specializes in orthopedic procedures requiring peripheral nerve blocks. The pediatric general surgery service performs minimally invasive surgery on a daily basis. Thoracoscopic and laparoscopic surgery on premature infants requires a very delicate anesthesia, which all of the RMHC anesthesiologists perform. Dr. Michael notes a unique quality about RMHC: Every pediatric patient has a board-certified pediatric anesthesiologist and CRNA’s are not used.

“We provide anesthesia for all age ranges: from premature infants too small to leave the neonatal intensive care unit to teenagers and everyone in between,” Dr. Michael says. “We work with the surgeon very closely, staying in constant communication. The surgical teams work together in what is like a wonderful dance to make sure even the most routine cases go as smoothly as possible. Everyone in the OR has the child’s best interest at heart, so the child can get back to what they are best at ... being a kid.”

Just like there are subspecialties in pediatric anesthesia, there are fellowship-trained subspecialties in general adult anesthesia, such as: cardiothoracic pain medicine and management, transplant, obstetric, regional, and neurosurgical anesthesia.

#### SPECIALIZED CARE FOR ADULTS

When it comes to adults on the campus, another team of anesthesiologists works with the adult surgical teams. Dr. Bailey says on any given day, the anesthesiologists might see everything from a finger foreign body removal to a colon resection, or a routine hysterectomy to a kidney transplant.

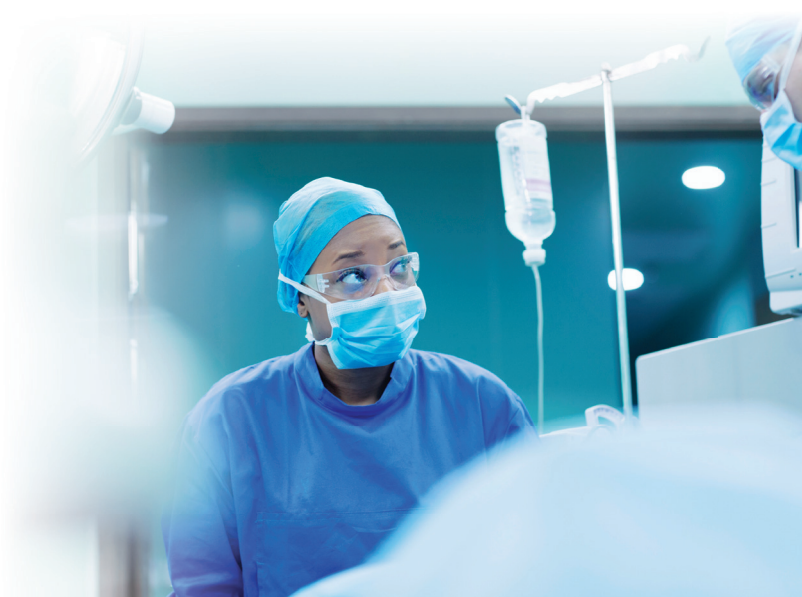The P/SL anesthesia team provides anesthesia and support for the same types of surgeries as Dr. Michael, as well as solid organ transplants and OB/GYN procedures. For adult patients on the campus, P/SL anesthesiologists and nurse anesthetists rotate in support of each specialty.

Anesthesiologists also play a role during labor and delivery, providing epidurals and pain control to laboring patients. P/SL offers high-risk moms delivery options in addition to routine deliveries. Labor and delivery can be a challenging place to manage routine patient care, emergency cesarean-sections and blood loss. On the deck, as it is called, the anesthesiologist, nurse anesthetist, OB providers and nurses all collaborate to take care of mom and baby (sometimes babies).

In addition to building relationships with patients and the unique care teams for adult and pediatric patients, there is also a spirit of comradery and helpfulness between RMHC and P/SL anesthesiologists. Though the age groups that each anesthesiology team serves are obviously very different, crossover can happen when another pair of hands is needed in any anesthetizing area or if a second opinion is requested.

“I know that I can always call Bridget (Bailey) or another colleague to assist regardless of the age of my patient,” Dr. Michael says. “Our anesthesiology teams have a strong mutual respect for one another and if any of us were in a time of need, a colleague would be willing to help.”

From pediatrics to labor and delivery, and from pre-op consultations to intraoperative management and post-op check-ins on the floor, P/SL and RMHC anesthesiologists are an integral part of the surgical patient care team — even if at first it seems their work is only done behind the surgical curtain.





# Highlighted Publications by Our Physicians

**M**any Presbyterian/St. Luke's Medical Center (P/SL) and Rocky Mountain Hospital for Children (RMHC) physicians are active in the publication of peer-reviewed articles, chapters and books. The following are highlights from around our campus (if you would like to share information on pieces you have published for future issues, please contact Tana Sykes, director of marketing/communications/PR for P/SL: 720-754-2557).

## SHAY BESS, MD ORTHOPEDIC/SPINE SURGEON

Shay Bess, MD, has co-authored more than 40 articles and presented 38 scientific podium discussions over the last 18 months. Following are the most recent:

1. Passias PG, Horn SR, Oh C, Lafage R, Lafage V, Smith JS, **Line B**, Protosaltis TS, Yagi M, Bortz CA, Segreto FA, Alas H, Diebo BG, Sciubba DM, Kelly MP, Daniels AH, Klineberg EO, Burton DC, Hart RA, Schwab FJ, **Bess S**, Shaffrey CI, Ames CP. Predicting the Occurrence of Postoperative Distal Junctional Kyphosis in Cervical Deformity Patients. *Neurosurgery*. 2020 Jan 1;86(1):E38-E46.
2. Cruz DL, Ayres EW, Spiegel MA, Day LM, Hart RA, Ames CP, Burton DC, Smith JS, Shaffrey CI, Schwab FJ, Errico TJ, **Bess S**, Lafage V, Protosaltis TS. Validation of the recently developed Total Disability Index: a single measure of disability in neck and back pain patients. *J Neurosurg Spine*. 2019 Dec 6:1-9.
3. Passias PG, Horn SR, Raman T, Brown AE, Lafage V, Lafage R, Smith JS, Bortz CA, Segreto FA, Pierce KE, Alas H, **Line B**, Diebo BG, Daniels AH, Kim HJ, Soroceanu A, Mundis GM, Protosaltis TS, Klineberg EO, Burton DC, Hart RA, Schwab FJ, **Bess S**, Shaffrey CI, Ames CP; International Spine Study Group. The impact of osteotomy grade and location on regional and global alignment following cervical deformity surgery. *J Craniovertebr Junction Spine*. 2019 Jul-Sep;10(3):160-166.



> Shay Bess, MD  
Orthopedic/Spine  
Surgeon

## DANIEL M. LERMAN, MD INSTITUTE FOR LIMB PRESERVATION/ ORTHOONE AT P/SL

Blank AT, **Lerman DM**, Shaw S, Dadrass F, Zhang Y, Liu W, Hung M, Jones KB, Randall RL. PROMIS scores in operative metastatic bone disease patients: A multicenter, prospective study. *J of Surgical Oncology*. 2018 August



> Daniel M. Lerman,  
MD Institute for  
Limb Preservation/  
OrthoONE at P/SL

## COLORADO BLOOD CANCER INSTITUTE (CBCI)

1. Hari P, **Matous JV**, Voorhees PM, Shain KH, Obreja M, Frye J, Fujii H, Jakubowiak AJ, Rossi D, Sonneveld P, Oprozomib in patients with newly diagnosed multiple myeloma. *Blood*. 2019 August
2. Flinn IW, Cherry MA, **Maris MB**, **Matous JV**, Berdeja JG, Patel M. Combination trial of duvelisib (IPI-145) with rituximab or bendamustine/rituximab in patients with non-Hodgkin lymphoma or chronic lymphocytic leukemia. *American J. of Hematology*. 2019 Sept.
3. Lonial S; Jacobus S; Fonseca R; Weiss M; Kumar S; Orlowski R.Z.; Kaufman JL; Yacoub AM; Buadi FK; O'Brien T; **Matous JV**; Anderson DM; Emmons RV; Mahindra A; Wagner LI; Dhodapkar MV; and Rajkumar SV. Randomized Trial of Lenalidomide Versus Observation in Smoldering Multiple Myeloma. *J. of Clinical Oncology*. 2019 Oct.
4. Flinn IW, Gribben JG, Dyer MJS, Wierda W, **Maris MB**, Furman RR, Hillmen P, Rogers KA, Iyer SP, Quillet-Mary A, Ysebaert L, Walter HS, Verdugo M, Klein C, Huang H, Jiang Y, Lozanski G, Pignataro DS, Humphrey K, Mobasher M, Kipps TJ. Phase 1b study of venetoclax-obinutuzumab in previously untreated and relapsed/refractory chronic lymphocytic leukemia. *Blood*. 2019 March.
5. Sandmaier BM, Kornblit B, Storer BE, Olesen G., **Maris MB**, Langston AA, Gutman JA, Petersen SL, Chauncey TR, Bethge WA, Pulsipher MA, Woolfrey AE, Mielcarek M, Martin PJ, Appelbaum FR, Flowers MED, Maloney DG, Storb R. Addition of sirolimus to standard cyclosporine plus mycophenolate mofetil-based graft-versus-host disease prophylaxis for patients after unrelated non-myeloablative haemopoietic stem cell transplantation: a multicentre, randomized, phase 3 trial. *Lancet*. 2019 Aug.



> Jeffrey V.  
Matous, MD



> Michael B.  
Maris, MD



(continued from page 5)



> Alireza Eghtedar, MD



> Peter McSweeney, MD



> Richard Nash, MD

6. Lemaistre CF, Chao JH, Cox T, Crus JC, Donnellan WB, **Eghtedar A**, Jolder J, Kambhampati S., Malik S., **Maris MB**, Rotto M, Slovic FT, Battiwalla M. Center Effects on Outcomes in the Treatment of Acute Myelogenous Leukemia (AML): A Multilevel, Community-Based, Case-Controlled Study. *Blood*. 2019 Nov.
7. Assassi S, Wang X, Chen G, Goldmuntz E, Keyes-Elstein L, Ying J, Wallace PK, Turner J, Zheng WJ, Pascual V, Varga J, Hinchcliff ME, Bellocchi C, **McSweeney P**, Furst DE, **Nash RA**, Crofford LJ, Welch B, Pinckney A, Mayes MD, Sullivan KM. Myeloablation followed by autologous stem cell transplantation normalizes systemic sclerosis molecular signatures. *Annals of Rheumatic Disease*. 2019 Oct.
8. Cohen JA, Baldassari LE, Atkins HL, Bowen JD, Bredeson C, Carpenter PA, Corboy JR, Freeman MS, Griffith LM, Lowsky R, Majhail NS, Muraro PA, **Nash RA**, Pasquini MC, Sarantopoulos S, Savani BN, Storek J, Sullivan KM, Georges GE. Autologous Hematopoietic Cell Transplantation for Treatment-Refractory Relapsing Multiple Sclerosis: Position Statement from the American Society for Blood and Marrow Transplantation. *Biology of Blood and Marrow Transplantation*. 2019 Feb.
9. Donnellan WB, Atallah EL, Asch AS, Patel MR, Yang J, **Eghtedar A**, Borthakur GM, Charlton J, MacDonald A, Korzeniowska A, Sainsbury E, Strickland DK, Jones S, Overend P, Adelman CA, Fabbri G, Travers J, Smith S, Pease JE, Cosaert J. A Phase I/II Study of AZD2811 Nanoparticles (NP) as Monotherapy or in Combination in Treatment-Naïve or Relapsed/Refractory AML/MDS Patients Not Eligible for Intensive Induction Therapy. *Blood*. 2019 Nov.
10. Berdeja JG, **Gregory TK**, Kambhampati S, Anz BM, Tarantolo SR, Meluch AA and **Matous JV**. A Phase 2 Study to Assess the Feasibility and Tolerance of the Combination of Elotuzumab, Lenalidomide, and Dexamethasone (ERd) in the Induction, Consolidation, and Maintenance Treatment of Transplant-Eligible Patients Newly Diagnosed with Multiple Myeloma (MM). *Blood*. 2019 Nov.
11. Vij R, Martin TG, Nathwani N, Fiala MA, Gao F, Deol A, Buadi FK, Kaufman JL, Hofmeister CC, Gregory TK, Berdeja JG, Chari A, Rosko AE. Ixazomib or Lenalidomide Maintenance Following Autologous Stem Cell Transplantation and Ixazomib, Lenalidomide, and Dexamethasone (IRD) Consolidation in Patients with Newly Diagnosed Multiple Myeloma: Results from a Large Multi-Center Randomized Phase II Trial. *Blood*. 2019 Nov.



> Tara Gregory, MD



12. Locke FL, Ghobadi A, Jacobson CA, Miklos DB, Lekakis LJ, Oluwole OO, Lin Y, Braunschweig I, Hill BT, Timmerman JM, Deol A, Reagan PM, Stiff P, Flinn IW, Farooq U, Goy A, **McSweeney PA**, Munoz J, Siddiqi T, Chavez JC, Herrera AF, Bartlett NL, Wiezorek JS, Navale L, Xue A, Jiang Y, Bot A, Rossi JM, Kim JJ, Go WY, Neelapu SS. Long-term Safety and Activity of Axicabtagene Ciloleucel in Refractory Large B-cell Lymphoma (ZUMA-1); A Single Arm, MultiCentre, Phase 1-2 Trial, The Lancet. 2018 Dec.

13. Bachier CR, Aggarwal SK, Hennegan K, Milgroom A, Francis K, **Rotta M**. 2019 Epidemiology and Real-World Treatment of Chronic Graft-Versus-Host Disease Post Allogeneic Hematopoietic Cell Transplantation: A US Claims Analysis. Blood. 2019 Nov.

14. Hamid MS, Rutherford SC, Kim S, Bartlett NL, Malecek MK, Watkins M, Maddocks KJ, Bond DA, Feldman TA, Magarelli G, Advani R, Spinner MA, Ahmed S, Stephens DM, Allen P, Patel K, **Tees MT**, Karmali R, Cheson BD, Yazdy MS, Strouse C, Pagel JM and Ramchandren R. North American Practice Patterns for PET-2 Positive Hodgkin Lymphoma. Blood. 2019 Nov.



> Marcello Rotta, MD



> Michael Tees, MD

## Expanding Liver Transplant Options for Adults and Children

**P**/SL is home to a liver transplant team that has completed more than 1,100 liver transplant surgeries. The treatment is offered for a wide range of liver conditions, including liver cancer, liver failure and liver disease brought on by autoimmune disease, hereditary conditions, hepatitis and alcohol abuse.

Now, RMHC has opened its pediatric liver transplant program. Dr. Thomas Heffron, who has completed over 500 pediatric liver transplants and 120 living donor surgeries, is joined by pediatric hepatologist Dr. Amber Hildreth. Dr. Hildreth has extensive training in pediatric liver transplant. Together, they offer both living donor options and ABO-incompatible transplants. Their approach can help children get access to critical transplant options sooner.

The unique program at RMHC allows for adult donors and the pediatric transplant recipient to be cared for under one roof.

Our P/SL and RMHC teams are recognized for exceptional patient outcomes and satisfaction. For more information, please call 720-754-2155.

Meet our RMHC/PSL solid organ transplant team.

L to R: Mark Jones (kidney), Avash Kalra (liver), Clark Kulig (liver), Vidya Bhandaram (kidney), Tom Heffron (liver), Bahri Bilir (liver), Max Assolati (liver), Ben Vernon (liver), Amber Hildreth (liver).



> Thomas Heffron, MD, Pediatric Surgeon



> Amber Hildreth, MD, Pediatric Hepatologist



# BE PROACTIVE: IT'S LIKE HAND HYGIENE FOR CYBERSECURITY

(Adapted from Health Industry Cybersecurity Practices: Managing Threats and Protecting Patients<sup>1</sup>)

According to *Medical Economics*<sup>2</sup> magazine, cyberattacks that focus on health records are common, and there are “specific [black] markets with well-established prices for health care records.”

Based on a 2019 report from Health and Human Services, 58 percent of malware attack victims are small businesses and 90 percent of small businesses do not use any data protection. Further, the report cites an IBM Security/Ponemon Institute study that says health care has the highest cost for data breaches — at \$408/record in 2018.

The report suggests 10 ways to mitigate these threats. For additional details, see reference links:

## 1. E-mail Protection System:

Cyberattacks often involve ransomware, which typically gets into a network through phishing scams (where someone from the outside tries to trick you to give out information). It is helpful to educate staff and run internal phishing test e-mails to make sure staff do not fall victim to phishing scams.

## 2. Endpoint Protection Systems:

Security software that helps to mitigate attack path for wireless and wired computer networks.

- 3. **Access Management:** Authentication and multifactor authentication for remote access.
- 4. **Data Protection and Loss Prevention:** Backup strategies and data use procedures.
- 5. **Asset Management:** Careful procedures to decommission assets and store inactive devices.
- 6. **Network Management:** Network profiles and firewalls, network segmentation.
- 7. **Vulnerability Management:** Software patch management and automated tools to scan web applications.
- 8. **Incident Response:** A security operations team.
- 9. **Medical Device Security:** Asset management, medical device management.
- 10. **Cybersecurity Policies:** General policies to guide your use of information systems in the office.

- 1. “Health Industry Cybersecurity Practices: Managing Threats and Protecting Patients.” U.S. Department of Health and Human Services and Healthcare and Public Health Sector Coordinating Councils; 12/2018; [healthsectorcouncil.org/wp-content/uploads/2018/12/HICP-Main-508.pdf](https://www.healthsectorcouncil.org/wp-content/uploads/2018/12/HICP-Main-508.pdf)
- 2. Shryock, Todd. “The growing cyber threat to physician practices.” *Medical Economics*. May 15, 2019; Volume 96, Issue 10; [www.medicaleconomics.com/news/growing-cyber-threat-physician-practices](https://www.medicaleconomics.com/news/growing-cyber-threat-physician-practices)

This special edition *Presbyterian/St. Luke's Medical Center and Rocky Mountain Hospital for Children Physician Report* is published by HealthONE.

This information is intended to educate readers about subjects pertinent to health, not as a substitute for consultation with a personal physician.

To provide feedback, please go to [PSLMC.com](https://www.pslmc.com) and click on “Contact Us.”

©2020 All Rights Reserved. Permission to reprint or quote excerpts granted by written request only.

11089/11090

Developed by StayWell

